



Veterinary Surgical Referral Practice

220 High House Road
Cary, NC 27513
(919)380-9494 www.vsrp.net

Cranial Cruciate Ligament Rupture

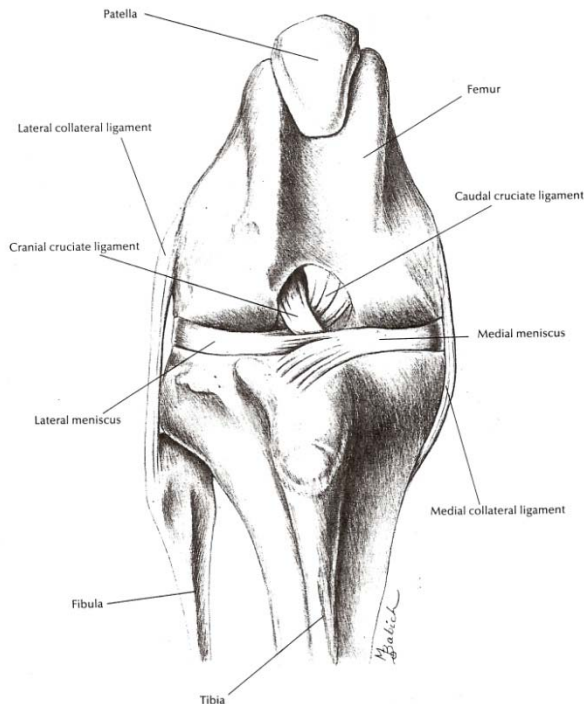
This information is provided to help you understand the condition that has been diagnosed in your pet. We find that many of the finer points that come up during the office visit can be overwhelming. By reading this at your leisure, we hope that you will be able to better understand the problem. We want you to understand how it might affect your pet, treatment alternatives, the care you will need to provide during recovery, and the expected prognosis. Please feel free to ask one of our veterinary technicians or surgeons if you have questions about any of the information provided here.

Anatomy

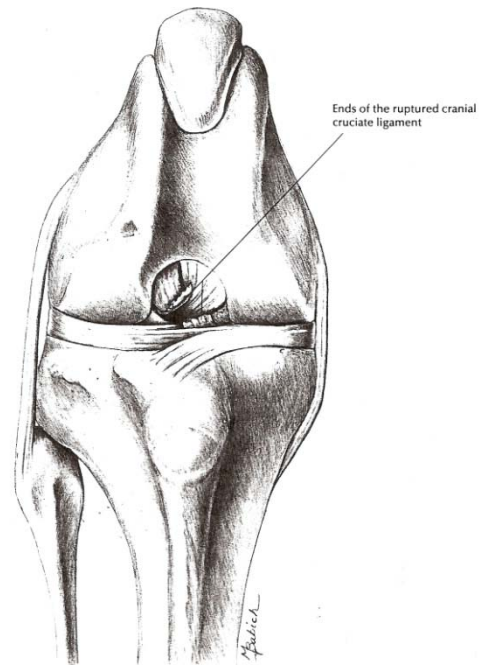
What is the Cranial Cruciate Ligament and what does it do? The cranial cruciate ligament (CrCL) is located inside the knee (stifle) joint and runs between the femur and tibia. The CrCL resists the forces that would cause cranial tibial thrust or movement of the tibia forward under the femur. In addition, working together with the caudal cruciate, the CrCL helps limit internal rotation of the tibia. The CrCL is very important for normal stifle motion and stability.

What is the Medial Meniscus? The medial meniscus is a crescent shaped fibrocartilage pad within the stifle joint. Along with the lateral meniscus, they act as cushions and stabilizers between the femur and the tibia. The medial meniscus is anchored in place differently than the lateral meniscus which leaves it vulnerable to damage if the CrCL is lost and the stifle joint is unstable.

Stable knee



Ruptured cruciate ligament



The Problem

Why does the cranial cruciate ligament rupture? In some dogs, the CrCL tears while working, playing, or competing. In these patients, the ligament is normal just before being subjected to a disruptive force; often a strenuous twisting movement during weight transfer or jumping. Infrequently, the CrCL will tear as the result of trauma to the stifle joint; usually hyperextension of the joint or a very selective blow from behind the stifle. The majority of dogs, however, that present with a torn CrCL are not athletes or working dogs and have no history of trauma. In these patients, the CrCL gradually fails over time with seemingly normal day to day activity. During this process, the dog may have periodic, transient lameness episodes or may show no signs at all. Eventually though, the patient develops what appears to be an acute, persistent lameness when the remainder of the failing ligament finally tears completely. The underlying reason for CrCL failure in this last, and by far largest, group remains poorly understood. What is more, we also now know that 60% or more of dogs that tear one CrCL are destined to tear the same structure in the opposite stifle joint within 2 years of presenting to their veterinarian for the first.

What will happen to the joint now? Once the CrCL begins to fail, the process will continue and once it fails completely, it will not heal or regenerate. The resulting instability causes repetitive micro-trauma to the joint surface cartilage, joint capsule, and other supporting structures in and around the joint; often including the medial meniscus. This leads to the release of substances that begin and sustain inflammation. Inflammatory cells enter the joint and cause further damage with release of more inflammatory mediators. The inflammation becomes well established, irreversible structural changes begin to develop in the joint surface cartilage and the bone beneath, and the process continues to perpetuate itself. The resulting discomfort and lameness leads to muscle, tendon, and ligament atrophy leaving the unstable joint with even less support. The body attempts feebly to repair the damage and reduce the instability by increasing the vascular tissue within the joint (synovial hyperplasia), making new bone and cartilage along the joint margins (bone spurs or osteophytes), and by producing scar tissue within and around the joint capsule. The end result of all of this is progressive osteoarthritis, joint stiffness, muscle atrophy and chronic lameness.

Treatment

First, it is important to know that once the CrCL begins to fail, the condition we are trying to manage from that point on is arthritis. How effectively we can help will depend on how rapidly and to what degree the arthritis develops. Since instability is the primary reason for the arthritis, the better we control this factor, the more successful we can be. For this reason, surgery to restore joint stability plays a very important part in managing this type of arthritis. A stable joint will be less uncomfortable, more reliable to use and can be less affected by arthritis as time goes on.

What surgical options are available to treat Cranial Cruciate Ligament injury? There are two basic types of joint stabilization surgery; static stabilization and dynamic stabilization. With the static techniques, we strive to replace the torn ligament in some fashion whereas with the dynamic techniques, we make structural changes in the limb that redirect weight-bearing forces to stabilize the joint; with this, replacing the ligament becomes unnecessary.

Extracapsular Nylon Imbrication: This is the most common static stabilizing technique performed today. With this technique, the torn ligament remnants, damaged portions of the medial meniscus, and any interfering bone spurs (osteophytes) are removed from the joint. The joint capsule is closed and a strand of heavy nylon material is passed around a small fabella bone behind the lateral femoral condyle and through a bone tunnel in the tibial tuberosity. The ends of the strand are passed through a crimp tube, tensioned to eliminate cranial tibial thrust, and secured by crimping the tube onto the ends of the nylon to form a closed loop running along the joint capsule surface in a direction similar to the original cruciate ligament. The nylon acts to resist the instability and provides a scaffold upon which properly oriented scar tissue forms. Ultimately, it is a combination of the nylon and scar tissue that stabilizes the joint. The success of this technique is, to a large degree, dependent on how stable the joint becomes. This, in turn, is a function of how effectively the nylon can maintain stability while the scar tissue forms. A number of factors such as limb and joint conformation, body weight, activity level, age, and concurrent health issues may have an influence. Clinical outcomes are generally acceptable although can be quite variable from patient to patient. What is more, the true success of this technique remains in question given that the osteoarthritis tends to advance in nearly every case.

Fibular Head Transposition (FHT): Developed by Dr. Gail Smith at Penn University, this static extra-capsular technique involves moving the top of the fibula forward along the lateral side of the tibia and securing it in this new location with a pin and wire. With this, the lateral collateral ligament, which is attached to the fibular head, is angled forward to mimic the orientation of the cranial cruciate and help resist cranial tibial thrust. This static stabilization is unique among the extracapsular techniques since the patient's own living tissue provides the stability from the beginning. While clinical results have not been significantly different from other, less complicated and less invasive extracapsular procedures, FHT remains a viable alternative to the others and may also be a good choice to salvage certain other extra-capsular techniques that have failed.

Tight Rope: In recent times, there has been a renewed interest in the extracapsular stabilization theme and some newer techniques are now available such as the Arthrex "Tight Rope". These new procedures have been developed in an attempt to improve the longer-term stability provided by the implanted material and, therefore, the clinical outcome when compared with the older extracapsular nylon technique. Although preliminary results are promising, the clinical studies to investigate the effectiveness of these newer techniques are ongoing.

Tibial Plateau Leveling Osteotomy (TPLO): Developed by Dr. Slocum in Eugene, Oregon, TPLO is the oldest and still most commonly performed dynamic stabilization technique. During the surgery, the medial meniscus is inspected for damage and any torn portions removed. The tibial plateau, containing the joint surface, is then rotated from its backward sloping position to a more level position. This is done by cutting the tibia with an oscillating curved bone saw blade, rotating the cut portion, and placing a bone plate to hold the rotated portion in its new orientation while the bone heals. This change in anatomy results in a redistribution of forces in the joint which neutralizes cranial tibial thrust. With this, the joint is no longer dependent on the CrCL for stability; therefore, replacing the ligament is no longer necessary.

Tibial Tuberosity Advancement (TTA): The TTA is a more recently developed dynamic technique discovered through collaborative research by biomechanical engineers and veterinary surgeons in Zurich, Switzerland. It came about as the result of state-of-the-art biomechanical studies of the canine stifle joint. With this technique, the front of the top of the tibia (tibial tuberosity) is cut and then advanced forward resulting in redirection of the straight patellar ligament. This change in anatomy results in redistribution of the forces within the stifle joint. With this, cranial tibial thrust is neutralized and replacement of the torn CrCL becomes unnecessary.

The TPLO and TTA procedures are both dynamic stabilization techniques but they differ in how they achieve stability. They both have their respective assets and liabilities. The reported assets of TTA are that it is a less invasive procedure, heals more quickly, achieves stability without increasing forces within the joint, and is less limb alignment sensitive when compared to TPLO. TPLO, on the other hand, seems to be an option for a wider variety of patients and, in our experience, tends to be less fragile in the early post-operative period when compared to TTA. In our surgery practice, we are prepared to offer both of these procedures and we can help you decide which may be best for your pet and for you.

Triple Tibial Osteotomy (TTO): TTO is the newest of the dynamic stabilization techniques. Similar to TPLO and TTA, it involves cutting and rearranging bone in the vicinity of the top of the tibia in order to effect a biomechanical change in the CrCL deficient limb to eliminate cranial tibial thrust and provide stability without replacing the torn ligament. This newest technique, in theory, makes use of the positive aspects of both the TPLO and TTA while better controlling the possible draw backs. The technique is relatively new and as a result it is not widely available with large number case studies still lacking. Yet, it holds promise for competing favorably with the more established procedures.

Post-operative Patient Care

After Surgery: Beginning shortly after admission, we implement a protocol of conscientious pain management for our patients to make their stay as comfortable as possible. To properly monitor recovery from anesthesia, assess your pet's comfort level, and to insure that your pet is beginning his or her recovery process properly, it is necessary, in most cases, for your pet to stay with us overnight or possibly two nights after surgery. Your pet will be monitored 24 hours a day by the doctors and staff members of our facility during their stay.

At Home: We would like you to be prepared for your pet's return home. In general, you should plan for 8 to 12 weeks of fairly strict activity restriction after surgery. Plan on keeping your pet in a crate, kennel, or smaller room (such as a "mud room" or utility room) when unsupervised. Short, slow leash walks 4 or 5 times a day on a level surface is recommended. If your pet tends to pull at the leash, consider a Gentle Leader, pinch collar, or similar device to discourage this behavior. Your pet may or may not have a full limb bandage depending on the procedure. Your pet will be provided medication for discomfort and possibly additional medications as needed during the post-operative period. When it is time for your pet to go home, we will set up a discharge appointment. This is a time we set aside to review with you the detailed home care instructions we will provide and to answer any questions you may have.

Risks

General anesthesia: We listen closely to medical histories, carefully review any provided medical records, do detailed physical exams, and perform pre-operative screening blood work and possibly radiographs all to identify and control anesthetic risk factors. Even with these measures, anesthesia remains a small, but present risk. For this reason, we use the safest general anesthetics available including Isoflurane and Sevoflurane. Our technical staff is highly experienced and well trained in the administration and monitoring of all types of sedation and general anesthesia. Your pet is carefully monitored by a formally trained and experienced licensed technician during anesthesia and is not left unattended the evening following their procedure. We have devised standard operating protocols with efficiency as a priority so your pet spends as little time under general anesthesia as possible.

Post-operative infection: Even with today's operating room technology and protocols, post-operative infection remains a small, but present risk occurring in about 1% of hospitalized veterinary surgical patients. It is very important that you give all post-operative medications as directed. As one of these medications, we routinely send patients home with a perioperative course of antibiotics to help guard against infection. It is also important to watch your pet closely to be sure he or she does not chew or lick at the incision. Indications of a possible post-operative infection may include lethargy, loss of appetite, excessive swelling, redness, or discharge from the incision. It is important to contact us or your family veterinarian if you suspect an infection is present.

Prognosis and General Considerations

Overall, we expect your pet to make slow steady progress after surgery. By the time you return for your follow-up visit at 6 to 8 weeks, we would expect to see 60% to 70% of normal weight bearing. Gradual and continued progress would be expected after this with an acceptable return of function by six months post-operatively. In our experience, the dynamic techniques (TPLO, TTA) have yielded better and more consistently favorable clinical results when compared to the extracapsular nylon. This seems especially so for the second stifle joint in those patients that tear their remaining CrCL.

The cause and treatment of CrCL disease remains a very active area of clinical research. While this is good, it does tell us that we still do not understand all of the reasons why this problem occurs and it also indicates that we have yet to find the best treatment. Osteoarthritis seems to be the practical problem with which we are faced. This condition, once present, cannot be reversed or "cured". This is a condition we manage and there are a number of steps we should consider. The most important factor is to try and eliminate or control the cause; this is the part surgery plays. The other steps, however, are also very important. Consider supplementing your pet's diet with a source of glucosamine. Most of these products contain other ingredients that are helpful as well. You may also give fish oil or flax seed oil to provide omega fatty acids. If your pet is overweight, work with your veterinarian to restore proper weight and body condition; this can make a significant difference in success or failure when managing arthritis over time. In general, achieving a moderated activity program will insure good muscle and tendon strength and keep metabolism up to control body weight with an acceptable amount of repetitive joint strain; this is a matter of "striking a balance". In the early phases of recovery, the help of a veterinary physical therapist should also be considered. This is especially helpful if your pet has established muscle atrophy, a poor body condition score, or advanced established osteoarthritis.